

COLLECTING TISSUES FOR SUDDEN AND UNEXPECTED DEATH INVESTIGATION

If the owners wish, they can have their rabbit's body back for burial after the following procedure. The *post-mortem* examination should take 10-20 minutes. Most of the time is spent stitching the incision. Sufficient quantity of formol saline (formalin; 10% neutral buffered formalin) is required. The tissues that need to be collected and submitted for histology are:

- Heart and lungs (whole organs)
- Piece of liver
- Whole kidney
- Piece of, or whole, spleen


Any other abnormal tissue of interest that is found during post-mortem examination can be taken and included and sent with the rest of the samples. The histopathologists are very willing to look at a range of tissues

PROTOCOL

- Find a large necked container (e.g a clean tub that had tablets in it or a plastic lunchbox). Fill it with 50 to 100mls formol saline to fix the tissue.
- A camera close to hand is an advantage. Photos of any abnormalities are always useful. A smartphone in a plastic bag with a window cut out over the lens works well.
- Make a midline skin incision from throat to pubis and expose the musculature beneath
- Free some of the skin from the musculature so that it is away from the incision. This prevents hair entering the body cavity and blood contaminating the fur.
- To open the abdomen, tent the skin for the initial small nick so that air can enter and the linea alba can be cut without opening the caecum. Extend the incision from xiphisternum to pubis. It can be helpful to incise the muscles following the line of the ribs and pubic brim. This allows the muscles to be folded back to expose more of the viscera without letting them displace too much. However, it is more difficult to repair the incision at the end of the procedure
- Look at the gross appearance of the viscera and presence of any fluid, blood or ingesta in the abdominal cavity.
- Is the stomach distended and filled with fluid and gas? If so, look for a small intestinal obstruction especially at the pyloric end of the duodenum. The common causes of obstruction are pellets of impacted fur or neoplasia. Gastric dilation can also be a sign of mucoid enteropathy or paralytic ileus.
- Examine the liver and assess its size and colour. Take a representative sample (about 2cm² of tissue) and place it in the formol saline for histopathology. If PCR testing is required, collect another liver samples (or two) to freeze (unfixed) and send to either PALS or BattLab for PCR testing. **Please note that from 23rd September 2018, free PCR testing is no longer available** under the Sudden or Unexpected Death Investigation.
- Lift the stomach and examine the spleen attached to the stomach by lesser omentum. Remove at least half the spleen and put into the formol saline.
- Move the guts to the right and find the left kidney (and adrenal gland) Note the size and surface of the kidney. Do the same on the other side. Remove at least one kidney, make a sagittal cut through the organ and put into formol saline.
- Examine the bladder and especially if a neutered female look for adhesions between the bladder and uterine/vaginal stump.
- Make a small nick in the diaphragm to allow the lungs to move away from the ventral thoracic wall and then incise alongside the sternum.
- Retract the ribs and sternum to open the chest cavity. Note the external surface of heart and pericardium. Look at all the lungs in situ.
- Incise up the neck to expose the trachea. Open the trachea to the pharynx to check for the presence of a foreign body. Note: The internal surface of the trachea in rabbits is naturally hyperaemic and red in colour.
- Section the trachea and lift/dissect out the pluck. Examine the heart and lungs grossly and preferably gently palpate the lungs. Are the lungs discoloured, collapsed and reddish/pin in patches, obvious tumour or abscess? Hyperaemia of the tracheal mucosa is a normal finding.

- Put the whole pluck into the formol saline but keep the cut edge of the trachea held in forceps and trickle formol saline into the trachea. Three to 5 mls is all that is needed to fix the lungs internally. Tie a ligature around the trachea.
- Preferably, inject a couple of mls of formol saline into the chambers of the heart, especially if the heart is large and the pericardial sac if it is not opened. Then immerse the whole pluck in formol saline.
- Repair the incision. Paper towelling can be used to pack the chest cavity and absorb any blood

Once the tissues for histopathology have fixed (more than 48 hours), the formol saline can be drained off and the fixed tissues placed in a sealable plastic bag. This bag is then surrounded by paper towels, placed into another sealable bag and finally a padded envelope. This seems to sufficient protection for the tissues. Post the fixed samples to Abbey Veterinary Services with the submission form.



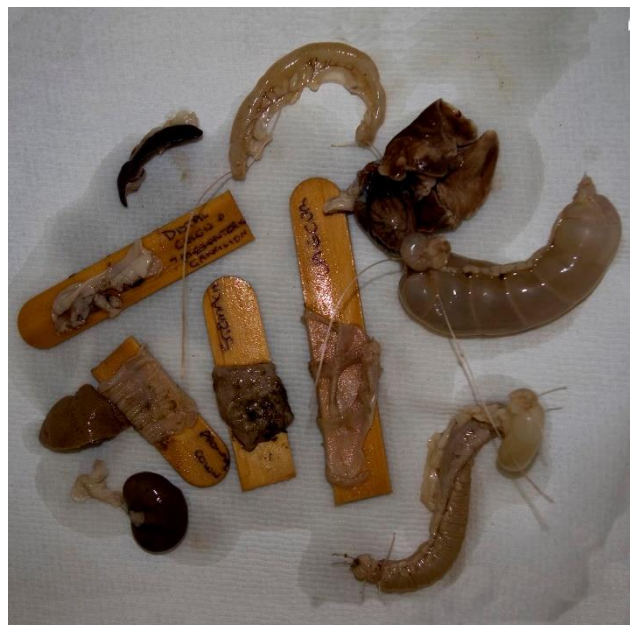ADDITIONAL TISSUES

The histopathologist is willing to look at any additional tissues that are submitted. If any abnormal tissue is found during post-mortem examination, it can be included and sent with the rest of the samples.

Intestinal pathology

Due to autolysis, meaningful results can only be gained from intestinal tissue if it is really fresh (i.e within 1 hour of death). It is often helpful to submit samples from different areas of the gastrointestinal tract. They need to be labelled so the histopathologist knows which parts the samples came from.

For best preservation, isolate the affected area of gut by tying off the whole piece of bowel. This allows the lumen of the gut to be injected with formol saline. Distend the bowel so that it keeps its form but is not under pressure. Remove and place in formol saline. Alternatively, open a length of gut and place it with the peritoneal aspect onto a wooden tongue depressor and fix. If need be, write in pencil on the wood prior to fixing the tissue onto it.



CNS tissue

Collection of CNS tissue is time-consuming. It is very destructive to remove a section of spinal cord or the brain so the body cannot be returned to the owner.

The pathologist needs the whole brain and/or a length of cord to work with. They need to know which part of the brain they are looking at so the tissue needs to retain its anatomical form. It needs to be properly fixed. It is unusual for random pieces of brain to be useful. It is possible to remove the back of the cranium and fill the cranial cavity with formol saline, while leaving the brain in situ. Sectioning the brain longitudinally through the sulcus allows the fixative to penetrate into deeper tissue. The whole head (after removing the skin) can then be immersed in formol saline before submission to the laboratory. This allows the pathologist to orientate the tissue. Alternatively, the brain can be removed and submitted. It is easier to remove once it is fixed